

The Fifth Day Fits - Aspects to a Forgotten Entity

Dubbudu A.¹, Venkata Rama Susarla B.^{2*}, Kulkarni Bhaskar Rao A.³, Dignesh Kumar B.⁴, Gattu H.⁵

DOI: <https://doi.org/10.17511/ijpr.2023.i01.03>

¹ Aranya Dubbudu, Department of Neonatology, Ankura hospital for Women and Children, Boduppal, Hyderabad, Telangana, India.

^{2*} Balaji Venkata Rama Susarla, Department of Neonatology, Ankura hospital for Women and Children, Boduppal, Hyderabad, Telangana, India.


³ Ajay Kulkarni Bhaskar Rao, Department of Neonatology, Ankura hospital for Women and Children, Boduppal, Hyderabad, Telangana, India.

⁴ Barala Dignesh Kumar, Department of Neonatology, Ankura hospital for Women and Children, Boduppal, Hyderabad, Telangana, India.

⁵ Harshitha Gattu, Department of Neonatology, Ankura hospital for Women and Children, Boduppal, Hyderabad, Telangana, India.

The fifth-day fits are defined as the onset of seizures between the fourth and sixth days of life in otherwise apparently healthy full-term infants.

Keywords: Rotavirus Infection, Fifth Day Fits, Seizures, Infants

Corresponding Author	How to Cite this Article	To Browse
Balaji Venkata Rama Susarla, , Department of Neonatology, Ankura hospital for Women and Children, Boduppal, Hyderabad, Telangana, India. Email: susbalaji3@gmail.com	Aranya Dubbudu, Balaji Venkata Rama Susarla, Ajay Kulkarni Bhaskar Rao, Barala Dignesh Kumar, Harshitha Gattu, The Fifth Day Fits - Aspects to a Forgotten Entity. Pediatric Rev Int J Pediatr Res. 2023;10(1):18-21. Available From https://pediatrics.medresearch.in/index.php/ijpr/article/view/737	

Manuscript Received
2023-02-04

Review Round 1
2023-02-07

Review Round 2
2023-02-14

Review Round 3
2023-02-21

Accepted
2023-02-28

Conflict of Interest
Nil

Funding
Nil

Ethical Approval
Yes

Plagiarism X-checker
19%

Note



© 2023 by Aranya Dubbudu, Balaji Venkata Rama Susarla, Ajay Kulkarni Bhaskar Rao, Barala Dignesh Kumar, Harshitha Gattu and Published by Siddharth Health Research and Social Welfare Society. This is an Open Access article licensed under a Creative Commons Attribution 4.0 International License <https://creativecommons.org/licenses/by/4.0/> unported [CC BY 4.0].



Introduction

Rotavirus infection was considered to be confined to the gastrointestinal tract, but many reports have shown that it may even cause extraintestinal manifestations including various neurological diseases, hepatitis, type 1 diabetes, myocardial dysfunction, pancreatitis and renal failure [1].

Only a few studies have examined the association between rotavirus infection and neurological symptoms in newborns[2-5].

Rotavirus infection has been suggested as a possible cause of 'fifth day fits' in the 1990s by Hermann et al. They observed a coincidental detection of rotavirus in the stools of several newborns presenting with fifth-day fits[2]

The term fifth-day fits was introduced in the 1980s to describe an epidemic of neonatal seizures that occurred in the 1970s[6,7].

Fifth-day fits are defined as the onset of seizures between the fourth and sixth days of life in otherwise apparently healthy full-term infants[7].

Case Report

A 5-day-old outborn male baby of 38 weeks 2 days gestation born to a G2P1 mother by caesarian section with a birth weight of 3 kgs with uneventful birth history born to non-consanguineous parents, presented on day 5 of life with complaints of multifocal clonic movements of all 4 limbs with each episode lasting for 10-15 seconds (total 7 episodes). No other significant family history was noted.

On examination, the Anterior fontanel was at level, with a head circumference of 33 cm, with no neurocutaneous markers and no focal neurological deficit. The Baby was managed as per unit policy. CSF analysis and EEG were within normal limits.

A pediatric neurologist opinion was taken who gave the provisional diagnosis of Neonatal refractory seizures with onset from day 5 of life with mild encephalopathy and advised for an MRI.

The baby underwent an MRI brain (plain) which showed multifocal restricted diffusion in bilateral Centrum semiovale and periventricular white matter suggestive of viral encephalitis.

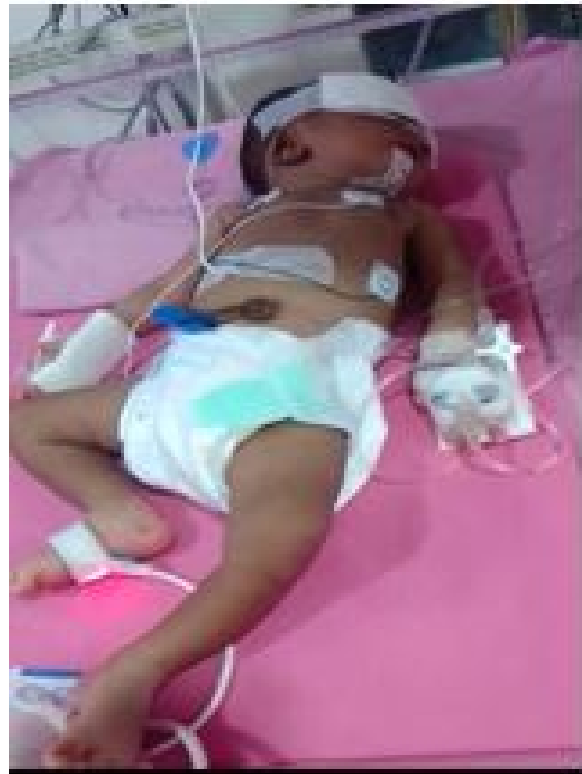

Figure 1: The baby at admission with multifocal clonic seizures of all 4 limbs.

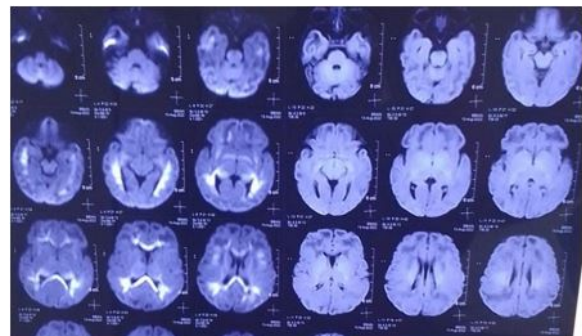


Figure 2: Note the restricted diffusion in bilateral centrum semiovale and periventricular white matter on diffusion weighted imaging suggestive of viral encephalitis.

Keeping the above picture in mind, stool PCR for rotavirus was sent which came positive. The baby was successfully discharged after a NICU stay of a week.

Discussion

Rotavirus-associated benign convulsions with gastroenteritis are characterized by febrile brief tonic-clonic to multifocal seizures between the 1st

To 5th sick days of gastroenteritis, tending to occur repetitively[1]. The main findings are (1) healthy term infants with seizures between 4 to 6 days of life (2)Gastroenteritis symptoms were not observed in most cases (3) Rotavirus was detected only in stool specimens (4) no evidence of CSF pleocytosis (5) Characteristic diffusion-weighted imaging (DWI) pattern on MRI [8].

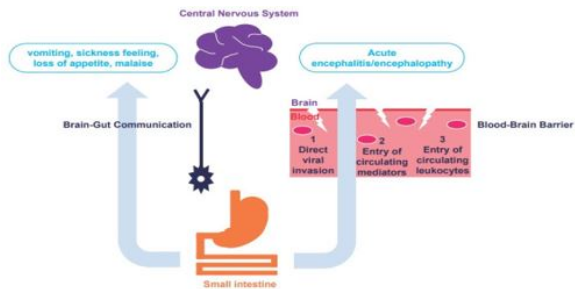


Figure 3. Schematic illustration of possible mechanisms by which rotavirus infection can cause central nervous system manifestation.

The following mechanisms have been proposed for Central nervous system manifestations following rotavirus infections (figure 3). First, CNS-driven symptoms such as vomiting, sickness, loss of appetite, and malaise are considered brain-gut communication in rotavirus infection. This includes activating the vagal nerves that project to regions of the brain via enterotoxin non-structural viral protein 4-dependent 5-hydroxy tryptamine release [9]. Second, previously described CNS complications are explained as direct CNS effects. Potential mechanisms include:(1) direct viral invasion into the CNS (2) CNS entry of deleterious brain-damaging mediators; and (3) CNS entry of activated circulating leukocytes [10]. The activation of brain microglia which release reactive oxygen and nitrogen species and cytokines which are toxic to the premyelinating oligodendrocytes is the principal initiating event in systemic infection/inflammation leading to White matter injury [11].The following mechanisms have been proposed for Central nervous system manifestations following rotavirus infections (figure 3). First, CNS-driven symptoms such as vomiting, sickness, loss of appetite, and malaise are considered brain-gut communication in rotavirus infection. This includes activating the vagal nerves that project to regions of the brain via enterotoxin non-structural viral protein 4-dependent 5-hydroxy tryptamine release [9]. Second, previously described CNS complications are explained as direct CNS

Effects. Potential mechanisms include:(1) direct viral invasion into the CNS (2) CNS entry of deleterious brain-damaging mediators; and (3) CNS entry of activated circulating leukocytes [10]. The activation of brain microglia which release reactive oxygen and nitrogen species and cytokines which are toxic to the premyelinating oligodendrocytes is the principal initiating event in systemic infection/inflammation leading to White matter injury [11].

Conclusion

Rotavirus-associated leukoencephalopathy should be considered in healthy term newborns who fulfil the following criteria: absence of perinatal asphyxia; seizure onset 4-6 days of age; and no known cause of neonatal seizures. In these babies, gastroenteritis symptoms were not observed in most cases, Rotavirus was detected only in stool specimens with no evidence of CSF pleocytosis and characteristic diffusion-weighted imaging (DWI) pattern as noted on MRI.[11].

Reference

1. Crawford SE, Ramani S, Tate JE, Parashar UD, Svensson L, Hagbom M, Franco MA, Greenberg HB, O’Ryan M, Kang G, Desselberger U, Estes MK. Rotavirus infection. *Nat Rev Dis Primers*. 2017 Nov 9;3:17083. doi: 10.1038/nrdp.2017.83 [Crossref] [PubMed][Google Scholar]
2. Burnett E, Parashar UD, Tate JE. Real-world effectiveness of rotavirus vaccines, 2006–19: a literature review and meta-analysis. *The Lancet Global Health*. 2020 Sep 1;8(9):e1195-202 [Crossref][PubMed][Google Scholar]
3. Tate JE, Burton AH, Boschi-Pinto C, Parashar UD, World Health Organization-Coordinated Global Rotavirus Surveillance N. Global, Regional, and National Estimates of Rotavirus Mortality in Children < 5 years of age, 2000 – 2013. *Clin Infect Dis* 2016; 62 Suppl 2: S96-105. [Crossref][PubMed][Google Scholar]
4. Gómez-Rial J, Sánchez-Batán S, Rivero-Calle I, Pardo-Seco J, Martínón-Martínez JM, Salas A, Martínón-Torres F. Rotavirus infection beyond the gut. *Infect Drug Resist*. 2018 Dec 24;12:55-64. doi: 10.2147/IDR.S186404 [Crossref][PubMed][Google Scholar]

05. 5. Herrmann B, Lawrenz-Wolf B, Seewald C, Selb B, Wehinger H. 5-Tages-Krämpfe des Neugeborenen bei Rotavirusinfektionen [5th day convulsions of the newborn infant in rotavirus infections]. *Monatsschr Kinderheilkd.* 1993 Feb;141(2):120-3. German [Crossref][PubMed][Google Scholar]
06. 6. Riedel F, Kroener T, Stein K, Nuesslein TG, Rieger CH. Rotavirus infection and bradycardia-apnoea-episodes in the neonate. *Eur J Pediatr.* 1996 Jan;155(1):36-40. doi: 10.1007/BF02115624 [Crossref][PubMed][Google Scholar]
07. 7. de Villiers FP, Steele AD, Driessen M. Central nervous system involvement in neonatal rotavirus infection. *Ann Trop Paediatr.* 2003 Dec;23(4):309-12. doi: 10.1179/027249303225007789 [Crossref][PubMed][Google Scholar]
08. 8. Verboon-Maciolek MA, Truttman AC, Groenendaal F, Skranes J, Døllner H, Hunt RW, Hayman M, Diepersloot RJ, van Loon AM, de Vries LS. Development of cystic periventricular leukomalacia in newborn infants after rotavirus infection. *J Pediatr.* 2012 Jan;160(1):165-8.e1. doi: 10.1016/j.jpeds.2011.08.053. Epub 2011 Oct 6. Erratum in: *J Pediatr.* 2012 Apr;160(4):710. Diepersloot, Rob J [corrected to Diepersloot, Rob J] [Crossref][PubMed][Google Scholar]
09. 9. North KN, Storey GN, Henderson-Smart DJ. Fifth day fits in the newborn. *Aust Paediatr J.* 1989 Oct;25(5):284-7. doi: 10.1111/j.1440-1754.1989.tb01478.x [Crossref][PubMed][Google Scholar]
10. 10. Pryor DS, Don N, Macourt DC. Fifth day fits: a syndrome of neonatal convulsions. *Arch Dis Child.* 1981 Oct;56(10):753-8. doi: 10.1136/adc.56.10.753 [Crossref][PubMed][Google Scholar]
11. 11. Yeom JS, Kim YS, Seo JH, Park JS, Park ES, Lim JY, Woo HO, Youn HS, Choi DS, Chung JY, Han TH, Park CH. Distinctive pattern of white matter injury in neonates with rotavirus infection. *Neurology.* 2015 Jan 6;84(1):21-7. doi: 10.1212/WNL.0000000000001107. Epub 2014 Dec 3 [Crossref][PubMed][Google Scholar]